Case Report ISSN (O):2395-2822; ISSN (P):2395-2814

Cytokeratin Positive Cystic Epithelioid Gastrointestinal Stromal Tumor Mimicking Gastric Carcinoma-Immunohistochemical Analysis and Review of Literatures.

Binay kumar[1], Upasna Chachra[2], Bhuvan[3]

[1]Professor, Department of Pathology, Govt. Medical College, Haldwani, Nainital.
[2]Resident, Department of Pathology, Govt. Medical College, Haldwani, Nainital.
[3]Associate Professor, Dept. of General Surgery, Govt. Medical College, Haldwani, Nainital.

Received: November 2016
Accepted: December 2016

Copyright: © the author(s), publisher. It is an open-access article distributed under the terms of the Creative Commons Attribution Non-Commercial License, which permits unrestricted non-commercial use, distribution, and reproduction in any medium, provided the original work is properly cited.

ABSTRACT

Gastrointestinal stromal tumor is biologically heterogeneous in both morphological appearance and clinical behavior. Immunohistochemical analysis and literature review was done to explore the necessity of mutation study. We present a case study of a 40 year old male presented with upper abdominal lump, exploratory laprotomy done and a large cystic mass involving transverse colon, omentum, stomach along with gross hemoperitoneum was found. Ruptured large cystic tumor mass measuring 19X16 cms was received for histopathological examination. Grossely the cystic mass show variegated outer nodular surface with attached piece of stomach and a segment of colon. Bright field microscopy show striking perivascular arrangement of tumor cells and geographical necrosis and the report signed out as undifferentiated carcinoma stomach. Battery of immunohistochemical markers was done. Tumor cells displayed diffuse positivity for CD117, DOG1, and pan-CK along with more than focal positivity for CD34 and negative for SMA, desmin, S-100, synaptophysin, chromogranin, Bcl-2, Ki- 67. Tumor turned out to be Cytokeratin positive epithelioid gastric GIST. Cytokeratins may be expressed in high grade GISTs rarely and CK positive GISTs must be differentiated from carcinomas, melanomas and a range of CK- positive sarcomas. A panel of immunohistochemistry markers is required for diagnosis and prognostication of the tumor.

Keywords: Cytokeratin, Epithelioid, Cystic GIST, Stomach.

INTRODUCTION

Gastrointestinal stromal tumors (GISTs) are mesenchymal neoplasms of GI tract. Two-thirds of GISTs arise from stomach and one fourth arises from small intestine. Colorectal lesions account for approximately 10% of GISTs. 95% of GISTs express CD117, 80% express bcl-2, 60% to 70% express CD34, 10% express S-100 protein, 50% express muscle specific actin, 5% express desmin, 25 and 37% of GISTs will react with the cytokeratin antibodies CAM 5.2 and CK8 respectively.[1] Immunoreactivity for Dog1 (a chloride channel protein) was found in 97.8% of scorable GISTs[2] and is a sensitive marker for unusual GIST subgroups lacking KIT or PDGFRA mutations. In tumors that are negative for both KIT and DOG1, mutational screening may be required to confirm the diagnosis of GIST. [3] The majority of GISTs harbor oncogenic mutations in KIT 2 and less commonly in platelet derived growth factor receptor alpha (PDGFRA). Spindle subtype correlates with KIT mutations and PDGFRA-mutated subtype displays epithelioid or mixed pattern.[1]

Name & Address of Corresponding Author
Dr. Binay Kumar
Professor Pathology,
Govt. Medical College,
Haldwani, Nainital,
Uttarakhand; India

The expression of cytokeratins in GISTs is rare and may lead to diagnostic confusion, thus pathologists should be aware that GISTs can occasionally express cytokeratins.[4] Here we describe a case of gastric malignant GIST with epithelioid morphology and perivascular growth pattern which was mimicking as diffuse undifferentiated gastric carcinoma and displayed diffuse positivity for CD117, DOG1, and pan-CK along with more than focal positivity for CD34.

CASE REPORT

A 40 year old male presented with upper abdominal lump and diagnosed on contrast-enhanced CT scan as pseudopancreatic cyst. Exploratory laprotomy was done and a large cystic mass involving transverse mesocolon, omentum, stomach along

with gross hemoperitoneum was found. Ruptured large cystic tumor mass along with attached colonic bowel segment was sent for histopathology [Figure 1].

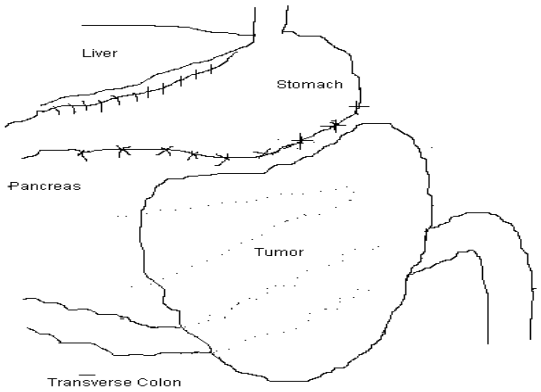

Figure 1: Diagramatic sketch depicting the preoperative positions of the tumor and adjacent organs.

Gross:

We received large cystic mass with attached bowel segment. The ruptured cystic mass measuring 19×16 cms and adherent bowel segment measuring 26×4 cms [Figure 2a]. The outer surface of cyst shows nodules of varying sizes and luminal side shows dark brown friable tissue pieces. There was a circumferential patch of stomach mucosa from greater curvature [Figure 2b].

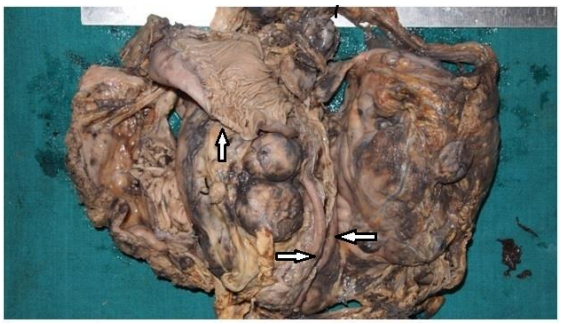

Figure 2a: Outer surface of the opened up cyst showing nodule s of varying sizes with adhered transverse colon (arrow).

Figure 2b: Outer surface of the opened up cyst showing nodule s of varying sizes with adhered circumferential patch of stomach mucosa from greater curvature (arrow).

On microscopy:

Tumor cells displaying pleomorphic hyperchromatic nuclei, small single to multiple nucleoli, moderate amount of granular eosinophilic cytoplasm, arranged partly as diffuse sheets, partly as nests and in peritheliomatous pattern in most of the areas [Figure 3a, 3b]. Frequent mitotic activity (30-40/10 hpf) and atypical mitosis are seen. In few areas geographical necrosis and muscularis mucosae infiltration with mucosa involvement was also noted (Fig. 4a). Differential diagnosis of diffuse infiltrating undifferentiated gastric carcinoma was made because two to three mucosal glands show multilayering & mild dysplasia but no well-differentiated adenocarcinoma- like glands noted [Figure 4b]. Muscularis propria abutting / infiltration also noted in occasional section [Figure 5].

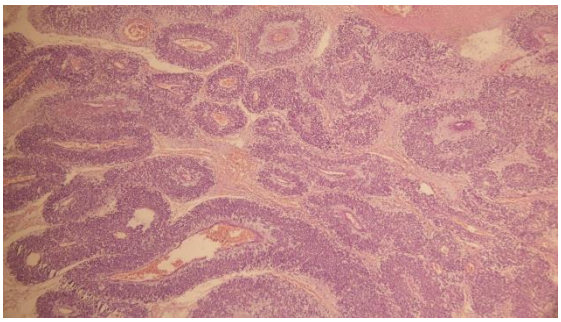

Figure 3a: Low power view showing perivascular / peritheliomatous arrangement of tumor cells. (H & E. stain 100 X).

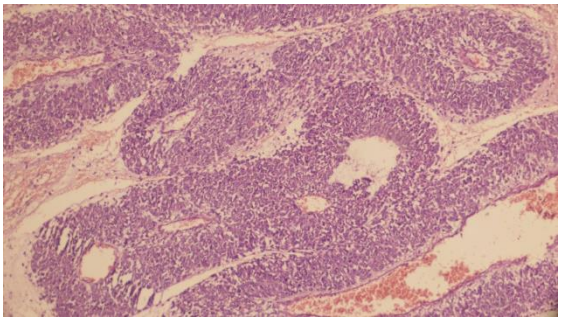

Figure 3b: High power view showing perivascular / peritheliomatous arrangement of tumor cells. (H & E. stain 400 X).

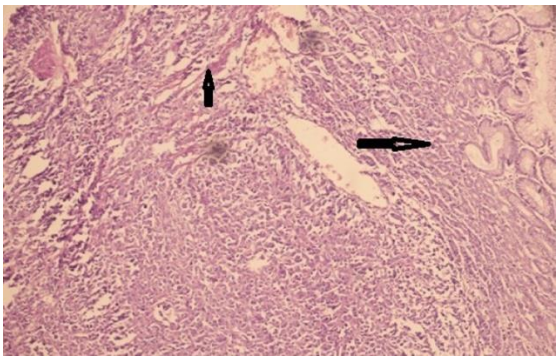

Figure 4a: Tumor cells infiltrating the muscularis mucosae (H & E. stain 100 X).

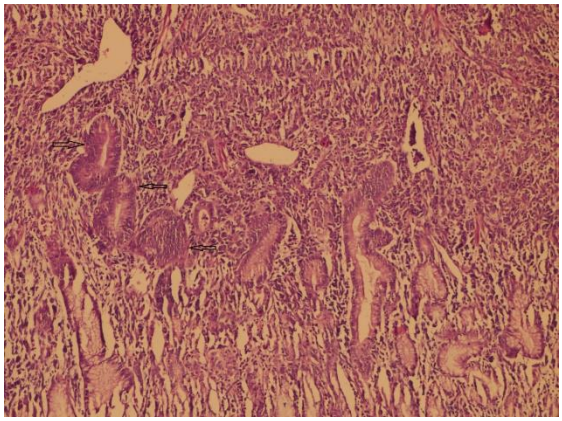

Figure 4b: Tumor reaching up to mucosa with reactive dysplasia of gastric mucosal glands. (H & E. stain 100 X).

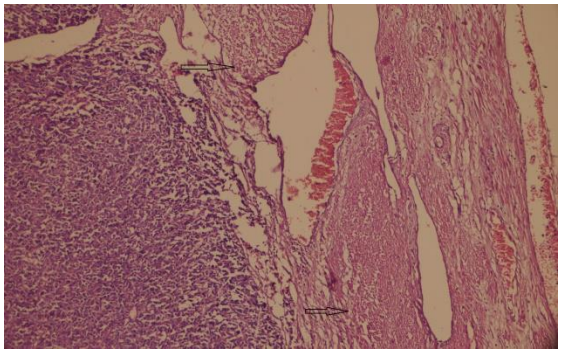

Figure 5: Sections from cyst wall showing sheet of tumor cells abutting/ infiltrating muscularis propria. (H & E. stain 100 X).

Result: On immunohistochemistry (Dako), tumor cells are diffusely strong positive for CD 117 [Figure 6], Dog1 [Figure 7], Pan-CK [Figure 8] and show more than focal positivity (> 10 %) for CD34 [Figure 9], focal positivity (< 10 %) for Bcl-2 [Figure 10], less than 5% positivity for Ki67. While negative for chromagranin, synaptophysin and S-100, SMA, desmin also. Report was signed out as CK- positive epithelioid GIST stomach with pertheliomatous growth pattern.

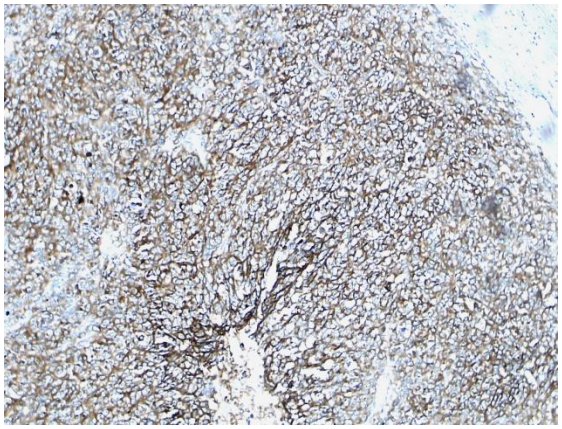

Figure 6: Diffuse C-kit positivity- low power view (c-kit 200 X).

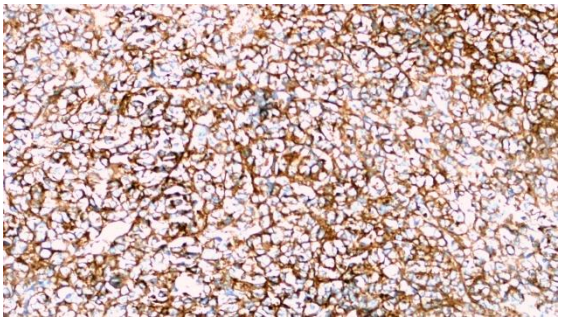

Figure 7: Diffuse DOG1 positivity- High power view. (DOG1 400 X).

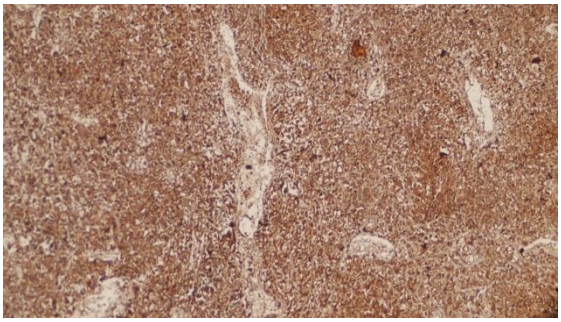

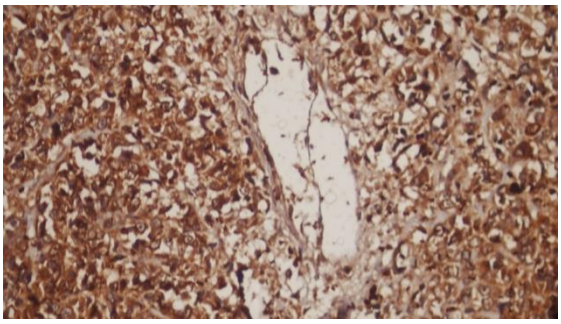

Figure 8: Diffuse Pan CK Positivity- low power view. (Pan CK 100 X).

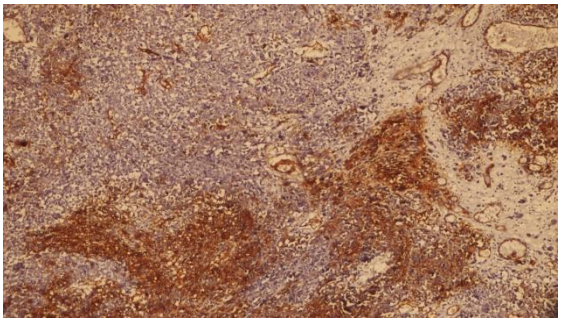

Figure 9: Sections show more than focal positivity (> 10 %) for CD34. (CD 34 100 X).

DISCUSSION

GISTs are the mesenchymal neoplasms of GIT arising from the interstitial cells of Cajal (GI pacemaker cells). Approximately 95% of the GISTs have gain of function mutations of KIT gene and are immunopositive for CD117. Rest, 5% have mutations of platelet-derived growth factor alpha (PDGFRA).[1] The overall sensitivity of DOG1 and

KIT in GISTs was nearly identical: 94.4% and 94.7%, and results in GISTs were generally concordant. Gastric spindle cell GISTs was nearly uniformly positive for both markers, whereas DOG1 performed slightly better in gastric epithelioid GISTs that included PDGFRA mutant GISTs. DOG1 expression was also generally present in the GI tract, Cajal cells and gastric surface epithelia, extragastrointestinal and metastatic GIST. In the intestinal GISTs, KIT was slightly more sensitive than DOG1. Negativity for both DOG1 and KIT was observed in 2.6% of GISTs of GI tract. KIT or PDGFRA mutations were detected in 11/24 DOG1-negative GISTs supporting the diagnosis of GIST. DOG1 was highly specific for GIST, but exceptional DOG1-positive other mesenchymal tumors included uterine type retroperitoneal leiomyomas, peritoneal leiomyomatosis, and synovial sarcomas.[5]

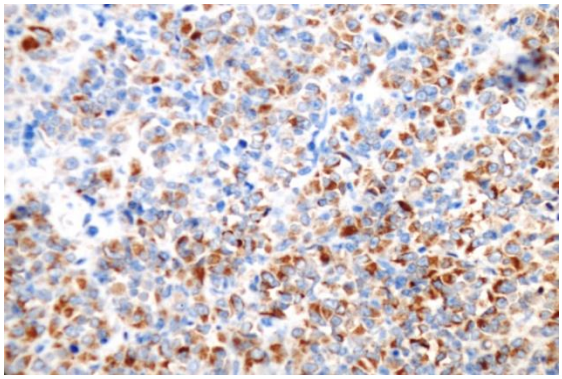

Figure 10: Sections show focal positivity (< 10 %) for Bcl-2. (Bcl-2 100 X).

Detecting individual mutations is valuable in predicting the prognosis and to determine whether they will respond to Imatinib mesylate therapy as the tumors expressing CD117 will respond to Imatinib (gleevec).[1] GISTs are morphologically heterogenous group of tumors with specific histogenesis. On the basis of morphology, GIST can be divided into following groups: spindle, epithelioid, mixed, pleomorphic, mesothelioma-like, oncocytic, small cell variant with rhabdoid phenotype. Pure morphological evaluation can cause diagnostic confusions as in our case with undifferentiated carcinoma. GISTs of stomach are generally benign but this is influenced by gastric location and size + mitotic count, frequency of malignancy is high in fundic location as compared to antral GIST and spindle cell type. Epithelioid GIST are common in stomach (based on >75% predominent cell type) and tend to be oriented in perivascular pattern. Most epithelioid GISTs are benign provided that the mitotic count does not exceed 5 mitosis per 50 hpf.[6]
A large 4 study of gastric GIST has delineated eight histological subtypes: 1. Sclerosing spindle cell GIST, 2. Hypercellular spindle cell GIST, 3. Palisading and vacuolated spindle cell GIST, 4. Sarcomatous spindle cell GIST, 5. Sclerosing epihelioid GIST, 6. Epihelioid GIST with dyscohesive pattern, 7. Hypercellular epithelioid GIST, 8. Sarcomatous epithelioid GIST and into eight groups based on maximum tumor diameter and mitotic activity.[7] Features which appear to 5 correlate with aggressive clinical behavior of gastric GIST are: mitotic activity, maximum tumor diameter, high nuclear grade, high cellularity, mixed cell type, mucosal invasion, tumor cell necrosis and stromal changes such as extensive myxoid change and absence of hyalinization.[6]
Immunohistochemical examinations have an important role not only in establishment of diagnosis but also in targeted treatment and clinical characterization of GIST, as suggested by Fletcher et al.[8] An immunohistochemical stain panel will help exclude undifferentiated gastric carcinoma[9,10] and other neoplasms that might be mistaken for GISTs, these include smooth muscle tumors, nerve sheath tumors, solitary fibrous tumor, desmoid fibromatosis, inflammatory myofibroblastic tumor, melanoma, PEComa and spindle cell carcinoma.[1]
Mori D. et al cited a case of gastric undifferentiated carcinoma where tumor cells were diffusely positive for cytokeratin, vimentin, c-kit and focally positive for chromagranin A and synaptophysin. They hypothesized that c-kit over expression of this tumor was attributed to neuroendocrine differentiation.[9] Hewer E et al commented on the findings of Mori D et al that since none of the 42 resected lymph nodes were involved with such large sized exophytic nodular mass- it would be somewhat more consistent with the expected behavior of a GIST than that of gastric carcinoma. They also reported a case suspicious for ulcerated gastric carcinoma which turned out to be GIST on gastroscopic biopsy where the tumor cells showed diffuse positivity for low molecular weight cytokeratin (CAM5.2), vimentin, c-kit, DOG-1 but negative for neuroendocrine markers and dysplastic change in adjacent gastric mucosa.[10] Similar findings were noted in our case except for mild dysplasia in occasional mucosal gastric glands. Nakajimo T et al reported a case of epithelioid gastric GIST showing extensive extramural growth in transverse mesocolon mimicking extragastrointestinal origin. But residual smooth muscle tissue from the gut wall in the tumor capsule was the categorical evidence of gastric origin.[11] As in our case also smooth muscle tissue was demonstrated in the occasional section from the tumor.
Miettinen et al cited a study of 1765 GIST cases and they found c-kit positivity in most the tumors (91%). A majority of c-kit negative tumors had epitheloid morphology and only 16 % were of spindle cell type. CD34 was positive in >82% and most had more than focal positivtity (>10 %), as

was in our case also. And highlighted that mucosal invasion is a relatively specific but not sensitive indicator of malignant behavior. Further epitheloid GIST biologically differed from spindle cell tumors by more commonly having PDGFRA than KIT mutations.[7] Penzel R et al observed significant association between c-kit mutation and spindle cell GISTs of intestine, between gastric origin epithelioid / mixed histology GISTs and PDGFRA mutation.[12]

G Rossi et al described a case of metastatic GIST that stained strongly for CD117, CD34 and cytokeratins in a patient previously diagnosed as gastric epithelioid angiosarcoma molecular analysis revealed c-kit mutation.[4] In a other study of 37 cases of GIST, 96.9% of cases showed diffuse strong positivity for vimentin, 88.5% cases positive for CD117, 76.6% cases showed positivity for CD34.[13] Lippai N. et al described a case of metastatic, haemorrhagic, ulcerative GIST with epithelioid appearance which displayed diffuse pan cytokeratin positivity and the diagnosis was confirmed by molecular analysis of c-kit mutation.[14] Nga et al reported a case of cytokeratin positive pleural metastatic GIST initially suspected to be lung carcinoma.[15] Miettinen et al found two cytokeratin 18 positive cases from 57 anorectal GISTs.[16] Sung Sun Kim et al also presented a case of intestinal mass located on serosal surface, diagnosed as biphasic GIST (mixed epithelioid and spindle cells), immunoreactivity for CK, c-kit and Dog1 was found. They concluded on the basis of literature review of single case studies that CK-immunoreactivity is more frequently noted in the epithelioid area than in the spindle cell area.[17] Aberrant expression of CK is known to be the result of aberrant synthesis of CK by tumor cells or cross-reactivity to other intermediate filament proteins.[18] Recently Sing Y et al published a study of 64 cases including 6 cases of gastric GISTs: total 10 cases (15%) demonstrated diffuse low molecular weight cytokeratin immunopositivity (CAM 5.2 and MNF-116) and 7/10 GISTs demonstrated pan-CK (AE1- AE3) immunoreactivity. In literature review they found 20 documented cases of gastric GISTs of which 6 showed AE1-AE3 immunoreactivity, 5 were CK 18/8 positive and 3 were CAM5.2 positive, 1 KLI positive. They hypothesized that cytokeratin expression exclusively in high risk GISTs is a consequence of tumor histomorphological progression that is associated with increasing chromosomal instability or sequential chromosomal alterations. They documented that CKs expression in GISTs with emerging dedifferentiated or anaplastic phenotypes may lead to diffuse immunoreactivity due to CKs 8 and 18. Also concluded that CK positive GISTs must be differentiated from carcinomas, melanomas and a range of CK- positive sarcomas such as: epithelioid angiosarcoma, leiomyosarcoma, malignant peripheral nerve sheath tumor, synovial sarcoma, alveolar rhabdomyosarcoma, malignant mesothelioma etc.[19] Haller F et al evaluated the prognostic significance of KIT- mutated epithelioid / mixed phenotype GIST of stomach and they found higher expression of G2-phase cyclin-B1, of the G1-M phase marker Ki67 in epithelioid/mixed GIST and a significant disease free survival as opposed to pure spindled morphology.[20] They suggested that genetic events enabling accelerated cell cycle progression through late phases of cell cycle may be present in KIT-mutated GISTs with epithelioid/mixed phenotype representing secondary growth pattern.[20] However, in our case Ki67 expression 18 was only < 5%, it may be due to selection bias. Thus GISTs may show a variety of histological growth patterns and they may be confused with undifferentiated carcinomas, variety of soft tissue tumors and immunostaining is essential both for diagnosis and treatment.

This case highlights that the pathologists should be aware that GISTs can occasionally express cytokeratins and molecular analysis of characteristic mutations can be helpful in the diagnosis and treatment.

REFERENCES

1. Gastrointestinal stromal tumors. Sternberg's Diagnostic Surgical Pathology V edn. p. 1304-06, 1420-23.
2. West R B, Corless C L, Chen X, Rubin B P, Subramanian S, Montgomery K, Zhu S, Ball C A, Nielsen T O, Patel R, Goldblum J R, Brown P O, Heinrich M C, Rijn M V D. The novel marker DOG1 Is expressed ubiquitously in gastrointestinal stromal tumors irrespective of KIT or PDGFRA mutation status. Am J Pathol 2004; 165:107-13.
3. Liegl B, Hornick JL, Corless CL, Fletcher CD. Monoclonal antibody DOG1.1 shows higher sensitivity than KIT in the diagnosis of gastrointestinal stromal tumors, including unusual subtypes. Am J Surg Pathol 2009 Mar; 33(3):437-46.
4. Rossi G, Sartori G, Valli R, Bertolini F, Bigiani N, Schirosi L, Cavazza A, Luppi G. The value of c-kit mutational analysis in cytokeratin positive gastrointestinal stromal tumor. J Clin Pathol 2005; 58:991-993.
5. Miettinen M, Wang ZF, Lasota J. DOG1 antibody in the differential diagnosis of gastrointestinal stromal tumors: a study of 1840 cases. Am J Surg Pathol 2009 Sep; 33(9):1401-8.
6. Trupiano J K, Stewart R E, Misick C, Appleman H D, Goldblum J R. Gastric stromal tumors: A Clinicopathologic Study of 77 Cases With Correlation of Features With Nonaggressive and Aggressive Clinical Behaviors. Am J Surg Pathol 2002; 26(6): 705-14.
7. Miettinen M, Sobin L H, Lasota J. Gastrointestinal stromal tumors of the stomach: a clinicopathologic, immunohistochemical, and molecular genetic study of 1765 cases with long-term follow-up. Am J Surg Pathol 2005; 29:52–68.
8. Fletcher CD, Berman JJ, Corless C, Gorstein F, Lasota J, Longley BJ, Miettinen M, O'Leary TJ, Remotti H, Rubin BP, Shmookler B, Sobin LH, Weiss SW. Diagnosis of

gastrointestinal stromal tumors: a consensus approach. Hum Pathol 2002; 33:459-465.

9. Mori D, Akashi M, Baba K. Morito K, Shibaki M, Hashimoto M, Nakamura A, Mawatari S, Sato S. Gastric undifferentiated carcinoma with diffuse c-kit overexpression and focal neuroendocrine differentiation. Pathol Res Pract 2013; 209(2):132-11.
10. Hewer E, Genitsch V, Schafer S C, Vajtal I. Cytokeratin-positive epithelioid GIST of the stomach- A comment on " Gastric undifferentiated carcinoma with diffuse c-kit overexpression and focal neuroendocrine differentiation." Pathol - Res Pract 2013; 209:467-468.
11. Nakajima T, Saito S, Sugiyama T, Murata K, Fukushima J, Horiuchi H. Epitheloid GIST of the stomach mimicking extragastrointestinal origin. Pathology International 2011; 61:677- 680.
12. Penzel R, Aulmann S, Moock M, Schwarzbach M, Reiker R J, Mechtersheimer G. The location of KIT and PDGFRA gene mutations in GIST is site and phenotype associated. J Clin Path 2005; 58:634-639.
13. Rauf F, Bhurgri Y, Pervez S. Gastrointestinal stromal tumors: a demographic, morphologic and immunohistochemical study. Indian J Gastroenterol 2007; 26:214-216
14. Lippai N, Fule T, Nemeth T, Benedek G, Malyi I, Padi E, Sapi Z. Keratin positive gastrointestinal stromal tumor of the stomach mimicking gastric carcinoma: diagnosis confirmed by c- kit mutation analysis. Diagn Mol Pathol 2008; 17:241-4.
15. Nga ME, Wong AS, Wee A, Salto-Tellez M. Cytokeratin expression in gastrointestinal stromal tumors: A word of caution. Histopathology 2002; 40:480-1.
16. Miettinen M, Furlong M, Sarlomo-Rikala M, Burke A, Sobin LH, Lasota J. Gastrointestinal stromal tumors, intramural leiomyomas, and leiomyosarcomas in the rectum and anus. A clinicopathologic, immunohistochemical, and molecular genetic study of 144 cases. Am J Surg Pathol 2001; 25:1121-33.
17. Kim S S, Choi D Y, Lee H J, Choi C. Cytokeratin positive gastrointestinal stromal tumor of biphasic morphology: A case report. The korean J of Pathol 2014; 48:375-8.
18. Fanburg-Smith JC, Majidi M, Miettinen M. Kertin expression in shwannoma: a study of 115 retroperitoneal and 22 peripheral shwannomas. Mod Pathol 2006; 19: 115-2
19. Sing Y, Ramdial P K, Ramburan A, Sewram V. Cytokeratin expression in Gastrointestinal stromal tumors: Morphology, meaning and mimicry. Indian J Pathol and micro 2014; 57(2):209-16.
20. Haller F, Cortis J, Helfrich J, Cameron S, Schuler P, Schwager S, Gunawan B, Fuzesi L, Agaimy A. Epithelioid/mixed phenotype in gastrointestinal stromal tumors with KIT mutation from the stomach is associated with accelerated passage of late phases of cell cycle and shorter disease-free survival. Modern pathol 2011; 24:248-255.

How to cite this article: Kumar B, Chachra U, Bhuvan. Cytokeratin Positive Cystic Epithelioid Gastrointestinal Stromal Tumor Mimicking Gastric Carcinoma-Immunohistochemical Analysis and Review of Literatures. Ann. Int. Med. Den. Res. 2017; 3(1):PT04-PT09.

Source of Support: Nil, **Conflict of Interest:** None declared